



NANOS

Patient

Brochure

Anterior Ischemic Optic Neuropathy

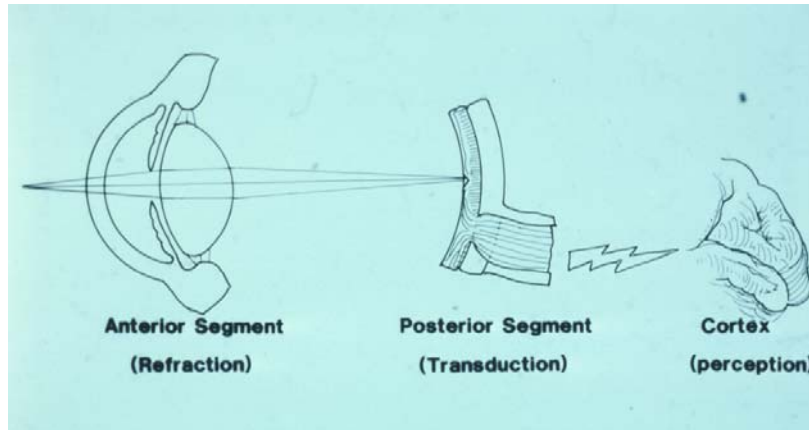
Copyright © 2015. North American Neuro-Ophthalmology Society. All rights reserved. These brochures are produced and made available "as is" without warranty and for informational and educational purposes only and do not constitute, and should not be used as a substitute for, medical advice, diagnosis, or treatment. Patients and other members of the general public should always seek the advice of a physician or other qualified healthcare professional regarding personal health or medical conditions.

Anterior Ischemic Optic Neuropathy (AION)

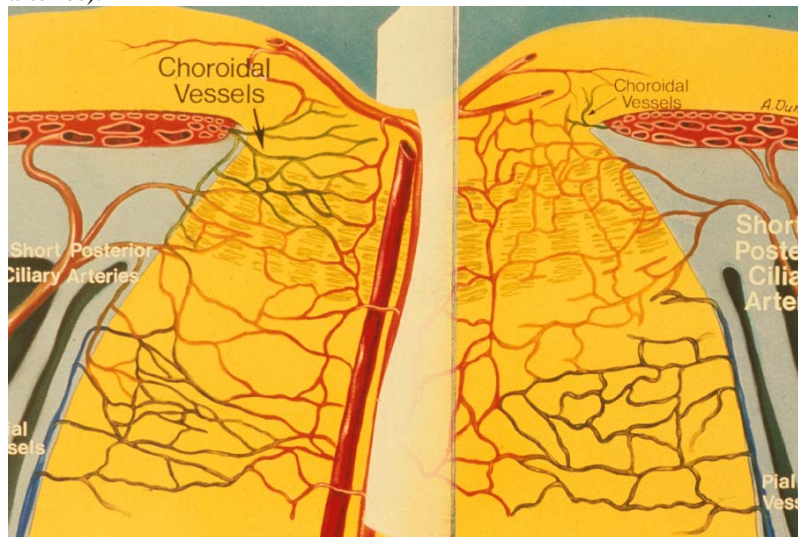
Your doctor thinks you have suffered an episode of anterior ischemic optic neuropathy (AION). This is the most common cause of sudden decreased vision in patients older than 50 years.

Anatomy:

We do not see with our eyes. We see with part of our brain that is capable of interpreting visual signals sent back from the eyes. This is located at the back of our head (the occipital lobes).



Information is transmitted from the eyes to the brain via the optic nerves. These nerves are composed of the long tube extensions (axons) of cells (ganglion cells) located within the inner lining of the eye (the retina) that exit the back of the eye at the optic disc. Each of the optic nerves receives blood supply from branches of the ophthalmic artery within each eye socket. The optic disc has a unique blood supply (the posterior ciliary arteries).



Physiology:

Loss of blood supply within the posterior ciliary arteries deprives the optic nerve tissue of oxygen and results in damage to part or all of the optic nerve. This is a small “stroke” in the optic nerve but unlike other strokes is unassociated with weakness, numbness, or loss of speech, nor is there an increased risk of a classic stroke later. It is also not associated with pain. Patients may become aware of decreased vision or difficulty seeing above or below the center of gaze. Loss of the blood supply results in swelling of the



optic disc, often associated with hemorrhages. The hemorrhages and swelling will go away leading to the development of a pale disc (optic atrophy). As the swelling resolves, some of the axons will be permanently lost.

We don't completely understand the cause of the loss of blood supply to the optic nerve. We do know that this happens more often in patients who are born with small optic discs. These episodes may occur when there is a sudden drop in blood pressure (following an operation or associated with blood loss after an accident). Patients who smoke, or who have diabetes or high blood pressure, may be at higher risk for AION.

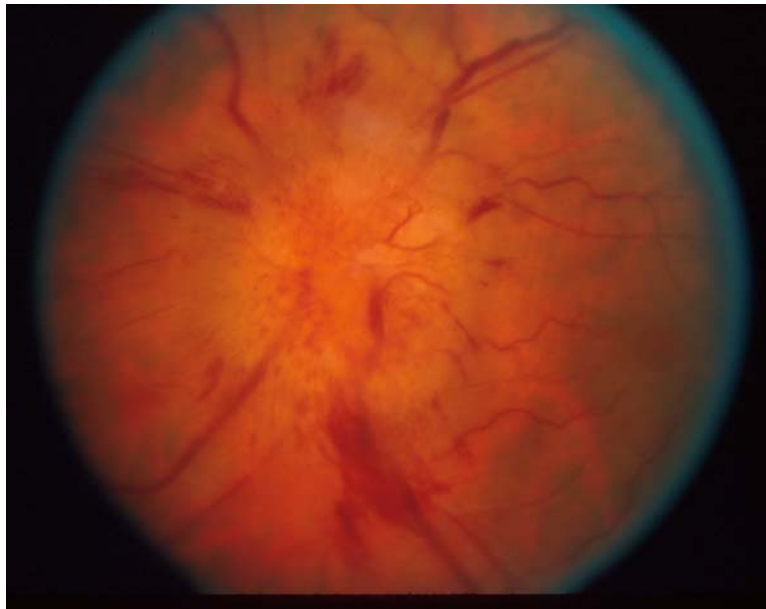
A small group of patients with AION may have inflammation involving the arteries. This is most common in very elderly patients who may also have symptoms of pain when chewing or scalp tenderness. These patients often have a prior history of episodes of visual loss and recovery, as well as weight loss, fever and pain in their shoulders and hips. In young patients a history of migraine might play a role.

Symptoms:

Most patients with AION notice a sudden disturbance in their vision. This may be recognized when the patient covers their opposite eye and becomes aware that the vision is blurred, dim, or dark; often above or below where they are looking. Uncommonly central vision remains normal. There should not be discomfort, redness, tearing, discharge or other change in the appearance of the eye. Patients with tenderness in their temples or pain when chewing may have a different cause of decreased vision and must bring these symptoms to the doctor's attention.

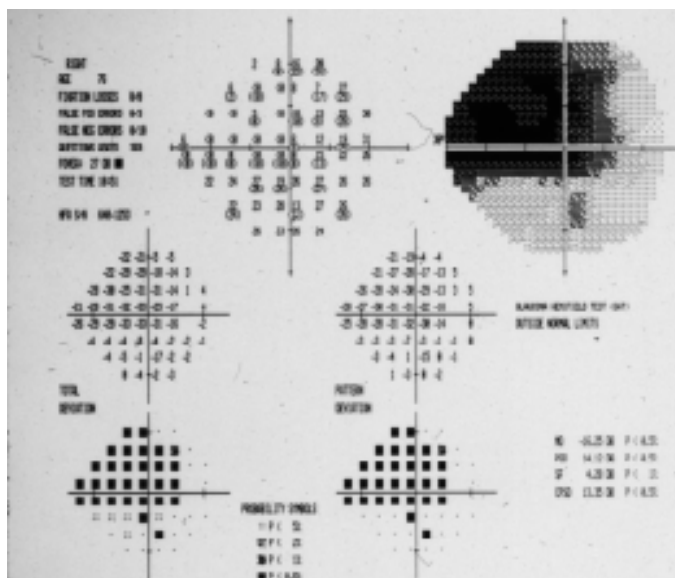
Signs:

Patients with AION have outwardly normal appearing eyes. Because of the decreased optic nerve function, however, the pupils may not react as well when light is directed into the affected eye. Swinging a flashlight between the two eyes will then show an "afferent pupillary defect." Your doctor will also notice swelling in the back of the eye.



This will go away over a period of weeks to months. The optic disc becomes pale after resolution of the swelling and hemorrhage. There may be some slight narrowing of the blood vessels at the back of the eye compared to the normal eye or its appearance before the episode. Visual field testing can identify the area of optic nerve dysfunction.





Diagnosis:

Often the optic disc of the other eye may appear small. This seems to be a risk factor that has been present from birth. In the case of typical AION no additional diagnostic imaging studies (CT or MRI scan) may be necessary. Blood pressure should be checked and if there are any unusual features other blood studies may be done. In elderly patients a blood test (sedimentation rate or c-reactive protein) can help assess the risk of giant cell arteritis.

Prognosis:

Most patients with ischemic optic neuropathy will have relatively stable vision. A recent study suggests that 40% of patients may expect to have some improvement in central vision. Unfortunately, much of the visual field defect (difficulty seeing above or below) will not improve. It may, however, become less noticeable with time, especially if the other eye is normal. A very small number of patients can have worsening of vision. This may be caused by sudden drop in blood pressure and anything that decreases oxygen carrying capacity (such as smoking).

In patients who have had AION there is a possibility of this happening in the other eye. Fortunately, this is not common (approximately 20% chance). Probably the best news is that it is very rare for a second episode of ischemic optic neuropathy to occur in the same eye.

Treatment:

Unfortunately, at this time there is no proven treatment for patients with AION. It has been suggested that aspirin (regular size or baby aspirin once a day) may decrease the chance of an episode in the opposite eye. It is important that the blood pressure be followed by your doctor (elevated pressure increases risk). On the other hand it is important that there be no sudden drop in blood pressure (overly aggressive treatment). This could cause worsening of vision or even involvement of the other eye. Smoking should be stopped.

Frequently asked questions:

What did I do to make this happen?

In most cases, there is nothing you or anyone else did to create this problem. The anatomy of your optic disc is something you were born with. It is possible that high blood pressure or smoking may have



increased your risk and, in rare cases, blood loss or sudden drop in blood pressure can also contribute. Ultimately, we still do not understand the trigger that will produce the ischemic event.

Will my vision get worse?

Within the first few days or weeks of the event, it is possible for there to be further worsening of vision. This, fortunately, is uncommon. To reduce this risk stop smoking and make sure that your blood pressure is adequately but not overly aggressively controlled. If your vision continues to worsen over more than a couple of weeks, be sure to contact your ophthalmologist.

Will my vision get better?

In patients with central loss, there is a 40% chance of improvement although the visual field tends to remain the same. It is likely that there will be persistent problems seeing above or below or in certain areas around where you are looking.

Is there anything I can eat or take to make this better?

At this time there is no known treatment that will result in improvement in the vision.

How can I prevent involvement of my other eye?

Taking an aspirin a day may reduce the chances. Avoiding cigarette smoke and proper treatment of elevated blood pressure may also help. Hopefully, in the future, we will have better means of making it less likely to have second eye involvement.

